

APPARATUS

An investigation into the length of standard tracheostomy tubes in critical care patients*

A. Mallick,¹ A. Bodenham,¹ S. Elliot² and J. Oram³

1 Consultant in Anaesthesia and Intensive Care Medicine, 2 Research Co-ordinator, 3 Specialist Registrar, Leeds General Infirmary, Leeds, UK

Summary

A number of problems have been reported with the use of standard length tracheostomy tubes in adult critical care patients. We measured the depth from the skin surface to the tracheal wall and the angle of the tracheal stoma during percutaneous tracheostomy. In vitro measurements were also performed on standard tracheostomy tubes. Comparison of in vivo and in vitro dimensions demonstrated that standard length tracheostomy tubes are too short for the average critical care patient. We recommend that both the stomal and intratracheal lengths should be made longer by approximately 1 cm and tubes should be redesigned to an angle of 110–120° to allow optimal tracheal placement.

Correspondence to: A. Mallick

E-mail: Abhiram.Mallick@leedsth.nhs.uk

*This study was presented at the 19th Annual Congress of European Society of Intensive Care Medicine in Barcelona, October 2006 (Mallick A, Bodenham A, Elliot S, Oram J. Tracheostomy tubes should be made longer. *Intensive Care Medicine* 2006; 32 (S1): 174) Accepted: 2 September 2007

Standard length tracheostomy tubes have traditionally been designed according to the perceived limits of anatomic proportions. They differ from one another in their overall length and angle (Fig. 1). Manufacturers typically state measurements on their packaging for the outer and inner tube diameter, the overall tube length from the securing flange to the tip, and the angle of the device. A description of standard nomenclature can be found in the British Standards Institute BSI (BSEN ISO 5366–1 : 2004) standard for tracheostomy design [1].

A tracheostomy tube in situ can be divided into two segments (Fig. 2), the section lying between the skin and the anterior tracheal wall (the stomal length) and the section lying within the tracheal lumen (the intratracheal length). The intratracheal length will depend on the total length of the tube, the size and shape of its cuff, the angle of the tube and the angle of the tracheal stoma in an individual patient. A preformed tube will not function well or lie comfortably if its stomal or intratracheal length are too short or too long.

We have encountered recurrent problems with standard length tracheostomy tubes in critical care patients

with tubes being functionally too short, prompting us to perform this study. We conducted measurements during percutaneous tracheostomy (PDT) to determine the optimum length and angle of a tracheostomy tube for a typical critical care patient with normal anatomy.

Methods

Following institutional Ethics Committee approval and informed relative assent, 50 patients scheduled for PDT were enrolled. Patients with a known difficult airway and those requiring ventilation with an $F_iO_2 > 0.6$ or PEEP > 10 cmH₂O were not studied. Morbidly obese patients (estimated body mass index > 35) and patients with severe coagulopathy were also not included in the study. Patients were anaesthetised with infusions of propofol and alfentanil, and paralysed with bolus doses of cisatracurium during the procedure; their lungs were ventilated with an F_iO_2 of 1.0. PDT was performed in a standard fashion using a Blue Rhino[®] dilator kit (Cook Critical Care, Letchworth, UK). A fiberoptic bronchoscope with camera and monitor display was used in all

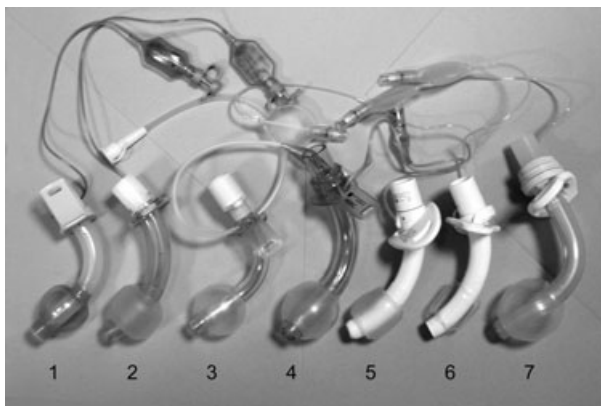

Figure 1 Various 8-mm internal diameter ‘standard length’ cuffed tracheostomy tubes: 1 Portex Blue line (Smiths Medical, Hythe, UK); 2 Portex Blue line ultra; 3 Mallinckrodt suction (Mallinckrodt Medical, Athlone, Ireland); 4 Mallinckrodt Perc; 5 Shiley (Mallinckrodt Medical, Athlone, Ireland); 6 Tracoe twist (Tracoe medical GmbH, Frankfurt, Germany), 7 Shiley tracheosoft XLT.

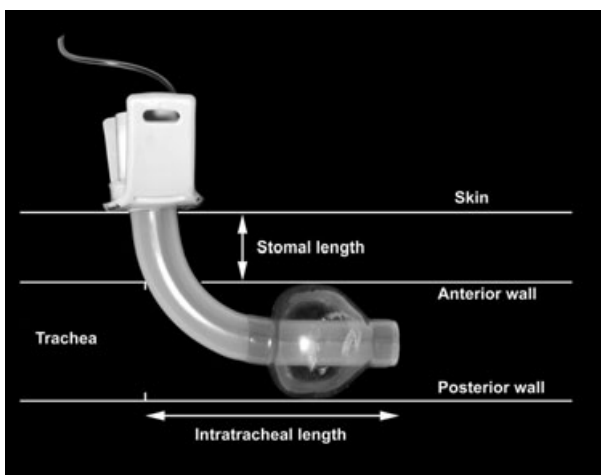


Figure 2 Demonstration of the stomal and intratracheal segments of a tracheostomy tube.

cases. Tracheal needle puncture was performed as near as possible to the midpoint between the cricoid cartilage and suprasternal notch. Following dilation of the tracheal stoma, a sterile, blunt-tipped orthopaedic depth gauge was inserted into the trachea to measure the distance from skin to anterior tracheal wall under endoscopic visualisation. The angle of the tracheal stoma from skin to the anterior tracheal wall was then estimated using blunt, preformed angled steel rods. Under endoscopic guidance the steel rod which aligned best with the stoma when its section within the trachea was pulled up against the anterior tracheal wall was selected. Following these

measurements, a Portex Blue Line tracheostomy tube (Smiths Medical, Hythe, UK) was inserted according to normal practice. The distance from the carina to the tip of the tracheostomy tube was then measured with the bronchoscope. This was inserted through the tracheostomy tube to the carina and then withdrawn to the level of tracheostomy tube tip. The withdrawn bronchoscope length was then measured, equating to the distance between carina and tube tip.

In vitro measurements were performed on the seven 8.0-mm internal diameter (ID) commercially available tracheostomy tubes available at our institution (Fig. 1). In addition to the overall length and angle of the tubes, we also measured external diameter, length of the cuff, length from flange to angle (where possible), and the total length. We performed these measurements with the cuff inflated to 20 cmH₂O. We measured the diameter using Vernier callipers. Length measurements were made by applying a nylon thread to the greater and lesser curvature of the tubes. The length of nylon was then measured using a ruler and the overall length was taken as the mean of these two values. Angles were measured using an orthopaedic device designed for the measurement of flexion in joints (Arthrometer, Mallinckrodt Medical, Athlone, Ireland). Some of these measurements were available from the manufacturers and these were found to correlate with our measurements.

Results

A total of 50 patients with a male/female ratio of 37 : 13 were enrolled in the study. Two patients were not included in the analysis as complete measurements were not possible. The patients’ ages ranged from 22 to 88 years (median 58 years). The estimated weight and measured heights (mean (SD)) were 78.5 (15.5) kg and 167.6 (7.8) cm, respectively. A size 8 tracheostomy tube was inserted in 48 patients and a size 9 in the remainder. Our unit commonly performs a trial extubation before replacing the tracheal tube with a tracheostomy. Twenty-nine patients (61%) had been considered unsuitable for a trial of extubation. Eleven patients (23%) had one trial, seven (14%) had two trials and one had three trials of extubation before tracheostomy. The average duration of translaryngeal intubation before performing tracheostomy was 7 (2) days. Tracheostomy was performed below the first tracheal ring in 14 patients (30%), below the second tracheal ring in 32 (66%) and below the third ring in two.

The distance measured from the skin to the anterior tracheal wall (stomal depth) was 25.6 (7.0) mm (mean (SD)). There was no difference in stomal depth between males (mean 25 mm, range 18–55 mm) and females (mean 21 mm, range 15–42 mm). There was no

Table 1 In vitro measurements of various 8-mm ID tracheostomy tubes with an acute bend.

Tube	Manufacturer	OD (mm)	Flange to angle length; mm	Cuff length; mm	Total length; mm	Angle
Portex Blue Line	Smiths Medical, Hythe, UK	11.0	9	23	82	90°
Portex Blue Line Ultra	Smiths Medical, Hythe, UK	11.9	9	18	75.5	90°
Mallinckrodt Suction	Mallinckrodt Medical, Athlone, Ireland	11.4	19	27	92	85°
Mallinckrodt Perc	Mallinckrodt Medical, Athlone, Ireland	11.6	20	25	80	100°

Table 2 In vitro measurements of various 8-mm ID tracheostomy tubes with a continuous curve.

Tube	Manufacturer	OD (mm)	Flange to angle length; mm	Cuff length; mm	Total length; mm	Angle
Shiley	Mallinckrodt Medical, Athlone, Ireland	12.2	N/A	25	81	135°
Tracoe twist	Tracoe medical GmbH, Frankfurt, Germany	11.4	N/A	24	76	140°
Shiley Tracheosoft XLT	Mallinckrodt Medical, Athlone, Ireland	13.3	N/A	26	105	135°

N/A, tube has continuous curve and no acute bend.

correlation between the stomal depth and estimated body mass index. The estimated angle of the stoma was 113 (9)°. The measured distance between the carina and the tip of the tracheostomy tube was 43 (8.4) mm (range 22–66 mm).

Clinical measurements were compared with in vitro measurements of the seven commercially available tracheostomy tubes (Tables 1 and 2). The flange to angle lengths of these tubes were shorter than the average measured stomal depth (Table 1). It was not possible to measure this length for tracheostomy tubes with a continuous curve rather than a clear angle (Table 2).

Discussion

The measurements in this study suggest that standard length tracheostomy tubes are likely to be too short for many ventilated critical care patients with apparently normal anatomy. Our data suggest standard tracheostomy tubes should be redesigned to increase both the stomal and intratracheal lengths by approximately 1 cm each and should be formed with an angle of 110–120°.

Standard length tracheostomy tubes are generally inserted either during an open surgical tracheostomy or by PDT. A tracheostomy tube that is too short may: (i) exert excessive pressure on the anterior tracheal wall around the stoma from the inflated cuff producing tissue damage, (ii) cause backward pressure of the tracheostomy tube tip onto the posterior tracheal wall leading to partial airway obstruction, mucosal erosion and granuloma formation; (iii) carry a risk of accidental decannulation

[2, 3]; (iv) make suctioning difficult; and (v) cause patient discomfort. Massive subcutaneous emphysema has been reported with fenestrated standard length tracheostomy tubes [4] when the short length of the tube may have led to the fenestrations lying in the stomal tissue rather than in the tracheal lumen, allowing air to leak into the tissues during periods of raised intrathoracic pressure. Ventilator tubing, HME filters and closed suction apparatus, when attached to a tracheostomy tube, frequently drag on the tube, increasing the risk of tube displacement. It has also been shown that significant tracheal obstruction with standard tracheostomy tubes can lead to a failure to wean patients from mechanical ventilation [5]. Weaning was facilitated when standard length tubes were replaced with longer, adjustable flange tubes [5].

Our in vitro tube measurements have shown that the length and angle of tracheostomy tubes with the same nominal size vary between different manufacturers. These tubes have, traditionally, been designed to accommodate patients with normal neck and airway anatomy. They appear, however, to be too short for a large proportion of ventilated patients. The flange-to-angle lengths of commercially available tubes are shorter than the measured average stomal depth (25 mm) in our patients. If it is too short, the angle of the tube may be positioned in the stomal tissue, with the tip of the tube directed towards the membranous posterior tracheal wall [6]. This can lead to partial dynamic obstruction of the tube [7]. A shorter flange-to-angle length also has an impact on the intratracheal length of such tubes. When in place the tube tip is separated from the carina by a mean distance of 43 mm.

This suggests there is a margin to increase the intratracheal length of these tubes to achieve an adequate intratracheal section, including the cuff, in the long axis of the trachea, whilst avoiding placing the tip too close to the carina and causing irritation and coughing.

Our *in vitro* measurements also showed differing angles of the tested tracheostomy tubes, with some tubes having a continuous curve. A number of tubes are rigid and are not readily deformed; others, however, are relatively flexible, allowing a degree of movement. Some are constructed from thermoplastic material, which may be relatively stiff at room temperature but which becomes more flexible at body temperature. It is worth noting that although tubes which are flexible may allow better conformation to individual anatomy, this requires pressure to be exerted on the tube by the airway. These pressures have never been measured. Our estimated measurements of angulation suggest that angles should be redesigned at 110–120° to enhance correct orientation of the intratracheal section of the tube.

Stomal depth depends on several factors: the site of the tracheostomy (if performed below the second or third tracheal ring the stomal length will be greater than if performed below the first tracheal ring); the angle of the stoma in relation to the trachea (less acute angles will lead to a greater stomal length); body size (a greater stomal depth can be expected in the obese); and the varying generalised oedema seen in most critical care patients. In this study stomal depth was measured with the neck extended. When the patient is sitting or mobilised with neck flexion, the stomal depth may increase and traction may be exerted on the tracheostomy tube with its cuff impinging on the anterior tracheal wall. To address this problem we recommend that there should be a low threshold for changing tracheostomy tubes which appear too short at the time of insertion or later in the patient's course. It is much easier to change a tube at the insertion stage rather than later, when changes without instrumentation are not generally encouraged until the stoma is well formed to prevent false passage of tubes.

An alternative would be the routine use of longer, flexible, adjustable flange tubes. However, currently available single-use dilator kits do not have a suitable loading dilator for placement of such tubes during PDT. A number of critical incidents have been reported with the use of these longer adjustable flange tubes [8–11]. This may be because these tubes have a longer stomal section with a normal intratracheal section. Clinical judgement by ICU physicians is generally used to decide which patients require a longer, adjustable flange tracheostomy tube. The objectivity of these decisions could be increased by the use of simple

measurements. During PDT the stomal depth can be estimated under endoscopic visualisation by measuring the distance from skin surface to the anterior tracheal wall with either the introducer needle or the first dilator. Such instrumentation should be manufactured with depth markers in centimetres. There are commercially available single-use depth gauges (Boston Medical Products, Westborough, MA, USA), but they are expensive for routine use. Endoscopy can be used to measure the distance from stoma to carina to ascertain whether a longer tube would be appropriate. Following tube placement, endoscopy from above via the glottis (to look for cuff alignment in the long axis of the trachea) and through the tube (to assess the distance to the carina, and the distal tube alignment in the trachea) is helpful in determining the optimal placement of the tube.

At present, commercially available kits do not have purpose-designed loading dilators for the placement of longer, adjustable flange tubes. To find a suitable loading dilator, one has to be chosen from serial dilator kits, but this is often found to be of inadequate length for the tube. Preformed longer, adjustable flange tubes have increased stomal lengths whereas the intratracheal segment remains relatively unchanged. If the stomal length is left too long, then the angle of these tubes may impinge on the posterior tracheal wall and the tube tip will be directed towards the anterior tracheal wall. Flexible tubes without a preformed angle may be advantageous in this respect. The potential advantages of longer tubes need to be balanced against their disadvantages, such as granuloma formation as these tubes can exert constant pressure on the tracheal wall [8].

In conclusion, the measurements in this study suggest that the lengths and angulation of standard design tracheostomy tubes are unsuitable for the average critical care patient and that they should be redesigned.

Acknowledgements

The authors would like to thank Cedric Russell from Smiths Medical International for his advice in relation to this study.

References

- 1 BSEN ISO 5366–1:2004: Anaesthetic and respiratory equipments: tracheostomy tubes. <http://www.bsistandards.co.uk> [accessed 2 February 2007].
- 2 Gallagher JE, Banerjee A, Stachowski E. Observed problems with the blue line ultra tracheostomy tube and inner cannula. *Anaesthesia and Intensive Care* 2000; **28**: 709–11.

- 3 Vey-Hong P, Raman R. Adjustable length tracheostomy tubes for the morbidly obese and thick neck patients; a prototype. *Otolaryngology – Head and Neck Surgery* 2001; **124**: 56–7.
- 4 Mostert MJ, Stuart H. Subcutaneous emphysema caused by a fenestrated tracheostomy tube. *Anaesthesia* 2001; **56**: 191–2.
- 5 Rumback MJ, Walsh FW, Anderson WM, Rolfe MW, Solomon DA. Significant tracheal obstruction causing failure to wean in patients requiring prolonged mechanical ventilation: a forgotten complication of long term mechanical ventilation. *Chest* 1999; **115**: 1092–5.
- 6 Sun KO. Obstruction of tracheostomy tube by tracheal wall after percutaneous tracheostomy. *Anaesthesia* 1996; **51**: 288.
- 7 Trottier SJ, Ritter S, Lakshmanan R, Sakabu SA, Troop BR. Percutaneous tracheostomy tube obstruction. *Chest* 2002; **122**: 1377–81.
- 8 Tibballs J, Robertson C, Wall R. Tracheal ulceration and obstruction associated with Bivona tracheostomy tubes. *Anaesthesia and Intensive Care* 2006; **34**: 495–7.
- 9 Perkins GD, Freeman JW, Walia S. Cardiopulmonary collapse associated with malpositioning of an adjustable flange tracheostomy tube. *Resuscitation* 2006; **69**: 357–8.
- 10 Sharma A, Elliot S, Mallick A. Kinking of a long tracheostomy tube can present as severe acute asthma. *Anaesthesia* 2002; **57**: 1238–40.
- 11 Coupe M. Critical incident involving an adjustable tracheostomy tube. *Anaesthesia* 2003; **58**: 388–9.