



Original Contribution

Bedside sonography by emergency physicians for the rapid identification of landmarks relevant to cricothyrotomy[☆]

Scott E. Nicholls MD^a, Timothy W. Sweeney MD^a,
Robinson M. Ferre MD^b, Tania D. Strout RN, BSN, MS^{a,*}

^aDepartment of Emergency Medicine, Maine Medical Center, Portland, ME 04102, USA

^bDepartment of Emergency Medicine, Wilford Hall Medical Center, Lackland AFB, TX 78236-9908, USA

Received 10 August 2007; revised 13 November 2007; accepted 14 November 2007

Abstract

Introduction: Cricothyrotomy is a difficult, infrequently performed lifesaving procedure.

Objectives: The objectives of the study were to develop a standardized ultrasound technique to sonographically identify the cricothyroid membrane (CM) and to evaluate the ability of emergency physicians (EPs) to apply the technique in a cohort of Emergency Department (ED) patients.

Methods: Four cadaveric models were used to develop a technique to accurately identify the CM. Two EPs then sonographically imaged 50 living subjects. Time to visualization of the CM and relevant landmarks, as well as perception of landmark palpation difficulty, were recorded.

Results: Fifty subjects were enrolled, and relevant structures were identified in all participants. The mean time to visualization of the CM was 24.32 ± 20.18 seconds (95% confidence interval, 18.59–30.05 seconds). Although a significant relationship between palpation difficulty and body mass index was noted, body mass index did not impact physician ability to identify the CM.

Conclusions: Emergency physicians were able to develop and implement a reliable sonographic technique for the identification of anatomy relevant to performing an emergent cricothyrotomy.

© 2008 Elsevier Inc. All rights reserved.

1. Introduction

Cricothyrotomy (CT) is an infrequently performed but essential procedure for an emergency medicine physician (EP) confronted with a difficult airway. Current techniques rely on digital palpation to properly identify relevant landmarks, including the cricothyroid membrane (CM) [1].

The need for CT most often occurs when conventional techniques for orotracheal intubation have failed. This may

occur when there is a copious amount of blood or vomitus in the oropharynx or if there has been disruption of supraglottic anatomy making intubation difficult, if not impossible. With the growing number of rescue airway devices and techniques, the failure to successfully orotracheally intubate a patient rarely occurs. Studies in the past decade describing airway management by EPs report CT rates of 0.4% to 1.2% [2–6]. As a result, many emergency medicine residents graduate from their training programs without ever having performed a CT in the clinical setting [7]. Because of the infrequency of this procedure, complications of emergency CT by EP are common, with rates ranging from 9% to 40% [1,8,9]. These factors coupled with the stress and difficulties

[☆] Reprints not available from authors.

* Corresponding author. Tel.: +1 207 662 7049; fax: +1 207 662 7054.
E-mail address: strout@mmc.org (T.D. Strout).

associated with successfully completing the procedure itself make CT a challenge for the EP.

Bedside ultrasound is increasingly being used to assist EPs in performing diagnostic and therapeutic procedures in a variety of settings [10-18]. Visualization of the CM has previously been described. However, such reports have been limited to abstract presentations at the yearly Society of Academic Emergency Medicine conference; and few details exist about the performance or success of imaging a wide variety of patients [19,20].

The purpose of this study was to develop a reliable and reproducible sonographic technique to identify the CM and then apply it to a variety of Emergency Department (ED) patients to determine if the sonographic technique was sufficiently accurate and efficient to be used in clinical practice. Our rationale was that if a reproducible bedside ultrasound technique was found to be both rapid and reliable in identifying the CM, then preprocedural ultrasound in anticipation of a difficult airway could potentially decrease the number of complications by directing the surgical incision and helping avoid important structures proximate to the CM. In addition, it could also potentially serve as an educational tool for resident physicians who may never have an opportunity to perform a CT during their training.

2. Methods

2.1. Study design

This study consisted of 2 phases. The first phase focused on developing a standardized technique for the sonographic identification of the CM using human cadavers, whereas the second was a prospective, observational trial examining the ability of EPs to obtain ultrasound images using the newly developed sonographic technique in a convenience sample of ED patients.

The second phase of the investigation, involving human subjects, was exempted by the Maine Medical Center Institutional Review Board; and the requirement for written informed consent was waived by the Board.

2.2. Setting and population

The first (technique development) phase of the study was conducted in a cadaver laboratory. Four cadaveric models were examined by manual palpation and then sonographically. The CM and surrounding structures were identified sonographically. Necks were then dissected to confirm and correlate the sonographic images to actual cadaver anatomy.

The second phase of the study was conducted in the Department of Emergency Medicine at a level-1, academic tertiary care referral center. The department houses an emergency medicine residency training program and had an

annual census of approximately 54 000 patients at the time of the study.

During the second phase, adult (≥ 18 years of age) patients present in the ED were eligible for study inclusion without regard to their presenting complaint on a convenience basis when study investigators were present for the purpose of data collection. Patients were excluded only if they were unable to speak and understand the English language or if they were unwilling to participate in the study protocol.

The physicians completing the study protocol were an attending EP and a third-year EP resident. The attending physician was not ultrasound fellowship trained and was not a member of the department's division of emergency ultrasound. Both the attending and resident physicians regularly attended monthly departmental ultrasound didactic sessions and use ultrasonography in their daily practice. Neither physician had formal ultrasound training such as Registered Diagnostic Medical Sonographer certification or completion of a formal ultrasound course.

2.3. Study protocol

2.3.1. Phase 1: technique development

During the first phase of the project, the necks of 4 cadaveric models were examined. A 10.5 MHz linear probe (38 mm) of a Sonosite Titan ultrasound machine (SonoSite, Inc, Bothell, WA) was used to obtain sonographic images on all cadaver models. Visual and palpable landmarks were compared with the sonographic images of the thyroid cartilage, tracheal rings, cricoid cartilage, CM, and other adjacent structures. Using this information, a protocol for ultrasound localization of the CM was created. Beginning in the sagittal plane, the thyroid

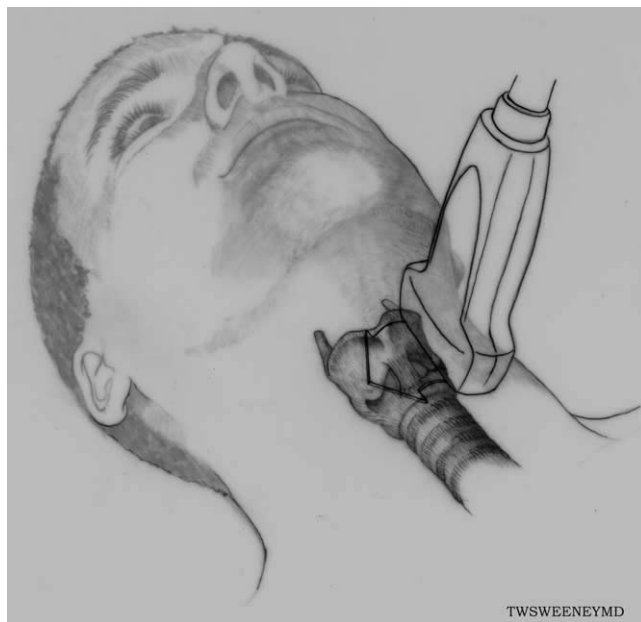

Fig. 1 Sonographic identification of landmarks in the sagittal plane.

Easy = Visual landmarks
Moderate = Requires light palpation of landmarks
Difficult = Requires deep palpation of landmarks
Impossible = Landmarks not palpable

Fig. 2 Physician perception of ease of landmark palpation.

cartilage, tracheal rings, and CM were identified (Fig. 1). Sliding the probe laterally in both directions into a parasagittal orientation, the borders of the CM were identified. Finally, the probe was then rotated 90° in a transverse orientation to verify the location of the CM. The CM boundaries were then marked, and blunt dissection of the cadaver was completed to confirm the accuracy of the sonographic images.

2.3.2. Phase 2: evaluation in ED patients

Using the technique that had proven accurate in the cadavers, an attending EP and third-year resident EP applied the technique to a convenience sample of ED patients using a 10.5 MHz linear (38 mm) probe of a SonoSite Titan ultrasound machine. Demographic data were recorded. Subject body mass index (BMI) was calculated from the standard metric formula: BMI = weight in kilograms/height in meters × height in meters. Success or nonsuccess of each scan, the time necessary to visualize the CM, and the time necessary to visualize other surrounding relevant structures, including the cricoid cartilage, thyroid cartilage, first tracheal ring, and the thyroid gland, were also recorded. Depth of tissue overlying the CM and subjective interpretation of the difficulty in palpating landmarks relevant to CT were recorded on a standardized data collection form (Fig. 2).

2.4. Data analysis

All data were entered into a Microsoft Excel (Microsoft Corp, Redmond, WA) spreadsheet and were analyzed using SPSS version 11.0 (SPSS, Inc, Chicago, IL) statistical software. Descriptive statistics including measures of central tendency, dispersion, and 95% confidence intervals (CIs) were calculated. The independent-samples *t* test was used to

	n (%)	Mean (SD)	95% CI
Sex			
Male	25 (50)	—	—
Female	25 (50)	—	—
Age	—	44.32 (19.56)	38.76-49.88
BMI	—	25.97 (6.06)	24.24-27.69
Neck circumference ^a	—	39.84 (5.02)	38.36-41.32

^a Circumference in millimeters.

Table 2 Time to visualization in seconds

Structure	Mean (SD)	95% CI ^a	Median	IQR
CM	24.32 (20.18)	18.59-30.05	18.0	14.25
Other structures ^b	33.32 (23.48)	26.65-39.99	22.5	25.75

IQR indicates interquartile range.
^a Exact method.
^b Cricoid cartilage, thyroid cartilage, first tracheal ring, thyroid gland.

compare group means. The Cohen κ statistic was calculated to determine agreement between the investigators on image acquisition. The Pearson correlation was used to examine the relationship between successful acquisition of images and subject characteristics, such as BMI.

3. Results

Fifty subjects were enrolled in the study, and all completed the protocol. The characteristics of the study sample are presented in Table 1. Interrater agreement between the physician investigators on image acquisition was 1.00, indicating perfect agreement.

3.1. Image acquisition and time

The CM, cricoid cartilage, thyroid cartilage, first tracheal ring, and thyroid gland were each identified sonographically in all 50 subjects by both physician investigators. Mean and median times to structure visualization are presented in Table 2. The maximum length of time needed to identify the CM in any case was 68 seconds, whereas the maximum time

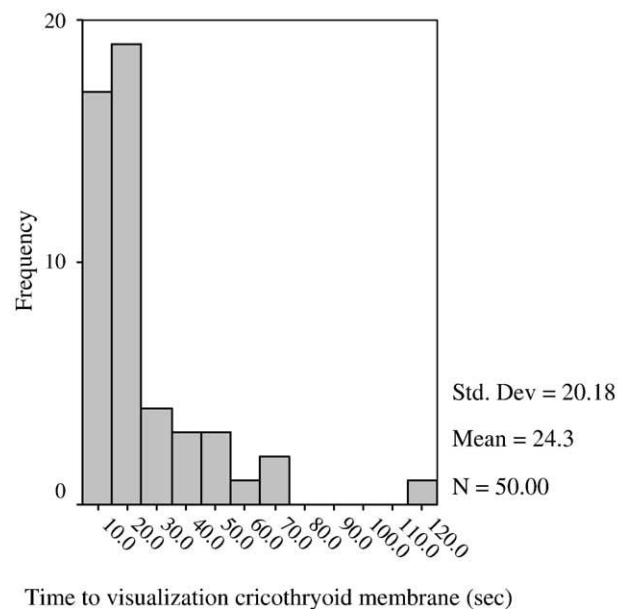


Fig. 3 Time to visualization of CM.

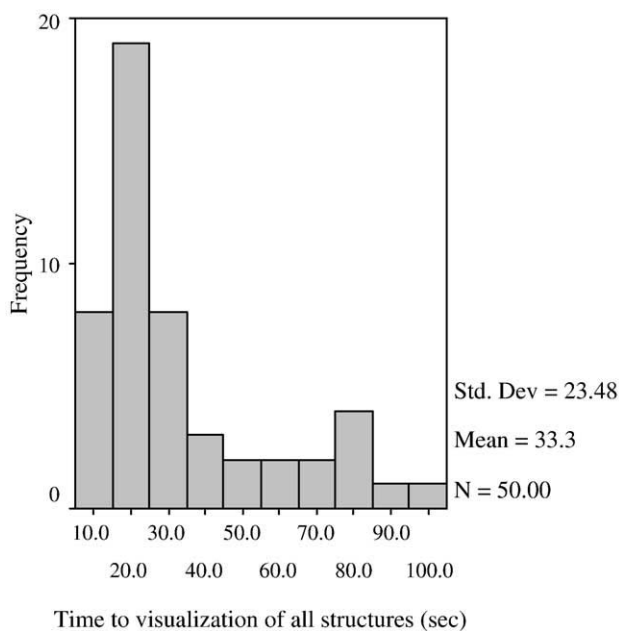


Fig. 4 Time to visualization of all structures.

necessary to identify all 5 structures in any case was 115 seconds. The mean depth of tissue overlying the CM was 2.33 mm. Figs. 3 and 4 depict visualization times as histograms, so as to depict the most frequently occurring values.

3.2. Time relationship to patient characteristics

The relationship between subject BMI and time to visualization of the CM was evaluated; and little, if any, correlation was found ($r = 0.262$). This was not a statistically significant result ($P = .066$). Although the relationship between BMI and time to visualization of all structures was statistically significant ($P = .027$), the strength of the correlation was weak ($r = 0.313$), with those subjects having the greatest BMIs also having the shortest visualization times. The variance shared between the variables (r^2) equals 0.098 or approximately 9.8%.

When examining the relationships between (1) tissue depth and time to visualization of the CM and (2) tissue depth and time to visualization of all structures, no statistically significant correlations were identified ($r = -0.074, P = .610$ and $r = -0.025, P = .864$, respectively). A statistically significant relationship between subject BMI and physician perception of landmark palpation difficulty was identified (Pearson $\chi^2 = 83.899, df = 56, P = .009$), with palpation difficulty increasing as BMI increased. Table 3 presents acquisition time as it relates to BMI and palpation difficulty.

4. Discussion

The findings in this study suggest that the CM and relevant structures can be quickly identified by EPs using a

standardized ultrasound technique. Anatomically, the CM is between the thyroid cartilage and the cricoid cartilage, both very echogenic structures. However, in our approach, we aimed to not only identify the CM but to define its borders. Although this took additional time, it also helped define the exact borders of this small structure. We found in the cadaver laboratory that this increased our confidence and our accuracy when compared with cadaver neck dissection. Whether this was due, at least in part, to our inexperience in identifying the CM and other airway structures is very probable. However, we found that identifying the borders of this small structure made our technique both accurate and reproducible, although no measures were explicitly used to measure this change in perception.

Body mass index and the amount of overlying tissue do not appear to have a significant effect on the time to visualization. However, it is interesting to note that in the 2 patients that were difficult to palpate, CM visualization was done even more rapidly than in those with easy to palpate structures. This is likely because there is additional tissue overlying the CM, allowing focus of the sonographic beam and better postimage acquisition resolution by the ultrasound machine. However, we were unable to find a consistent relationship.

Most importantly, this study suggests that ultrasound could potentially serve as an adjunct to palpation of the CM in patients where a difficult airway is anticipated. Ultrasound is both efficient and accurate at identifying the CM regardless of the patient’s neck circumference or physician’s ability to palpate the CM. Sonographically locating the CM and marking its location before proceeding with rapid sequence induction in patients where a difficult airway is anticipated could potentially decrease the time to perform CT if attempts at orotracheal intubation fail and reduce technical complications of performing the procedure, which have been reported to be as high as 40% [9].

Table 3 Image acquisition, BMI, and ease of palpation

Ease of palpation	n (%)	Mean BMI	Mean acquisition time (s)	Mean tissue depth (mm)
Easy	18 (36)	23.77 ± 2.68, (22.44-25.11) ^a	19.78 ± 14.95, (12.34-27.21)	38.33 ± 4.87, (35.91-40.76)
Moderate	30 (60)	26.86 ± 7.07, (24.22-29.50)	27.37 ± 23.06, (18.76-35.98)	40.42 ± 5.33, (38.43-42.41)
Difficult	2 (4)	32.25 ± 6.01, (23.98-40.58)	19.50 ± 6.36, (10.68-28.32)	44.75 ± 0.35, (41.57-47.93)
Impossible	0 (0)	–	–	–

^a All values reported as mean ± SD, (95% CI).

4.1. Limitations and future questions

There were several limitations to this study. The ultrasound procedure was performed by only 2 EPs with special interest in this procedure in a controlled setting. The ability to visualize structures in the neck should be evaluated in more physicians with varied levels of ultrasound training and experience. In addition, because of the infrequent occurrence of this procedure, we have not identified anything in the literature describing an actual case where landmark identification by ultrasound was used to assist in the performance of a CT in a living patient. Therefore, the use of ultrasound for this technique is still theoretical and may not actually be of benefit in performing the actual procedure. However, given the frequency with which CT occurs as a result of failed orotracheal intubation, it would be difficult to adequately power a study to detect a significant difference in patient outcomes using this technique. A prospective case series may provide evidence that there is some utility in using preprocedural ultrasound for this indication.

5. Conclusions

Using a cadaveric model, we were able to develop a standardized technique for the sonographic visualization of the CM and other structures relevant to CT. In a cohort of ED patients, 2 EPs were then able to apply this technique to rapidly obtain sonographic images of anatomy relevant to CT. Meaningful correlations between BMI and time to image acquisition were not identified.

Acknowledgment

The authors gratefully acknowledge the support of William B. Owens, MD, who provided expertise and advice during the planning and conduct of this investigation. In addition, we thank Vikhyat Bebarta, MD, for his thoughtful comments on drafts of this manuscript.

References

- [1] Mace SE, Hedges JR. Cricothyrotomy and translaryngeal jet ventilation. In: Roberts JR, Hedges JR, editors. *Clinical procedures in emergency medicine*. 4th ed. Philadelphia: WB Saunders; 2004. [Chapter 6-Electronic Edition].
- [2] Calderon Y, Gennis P, Marinex C, et al. Intubations in an emergency medicine residency: the selection and performance of intubators. *Acad Emerg Med* 1995;2:411-2.
- [3] Sakles JC, Laurin EG, Rantapaa AA, et al. Airway management in the emergency department: a one year study of 610 tracheal intubations. *Ann Emerg Med* 1998;31:325-32.
- [4] Tayal VS, Riggs RW, Marx JA, et al. Rapid-sequence intubation at an emergency medicine residency: success rate and adverse events during a two-year period. *Acad Emerg Med* 1999;6:31-7.
- [5] Sagarin MJ, Chiang V, Sakles JC, et al. Rapid sequence intubation for pediatric emergency airway management. *Pediatric Emergency Care* 2002;18:417-23.
- [6] Levitan RM, Rosenblatt B, Meiner EM, et al. Alternating day emergency medicine and anesthesia resident responsibility for management of the trauma airway: a study of laryngoscopy performance and intubation success. *Ann Emerg Med* 2004;43:48-53.
- [7] Chang RS, Hamilton RJ, Carter WA. Declining rate of cricothyrotomy in trauma patients with an emergency medicine residency: implications for skills training. *Acad Emerg Med* 1998;5:247-51.
- [8] Bair AE, Panacek E, Wisner D, et al. Cricothyrotomy: a 5-year experience at one institution. *J Emerg Med* 2003;24:151-6.
- [9] McGill J, Clinton JE, Ruiz E. Cricothyrotomy in the emergency department. *Ann Emerg Med* 1982;11:361-4.
- [10] Leung J, Duffy M, Finckh A. Real-time ultrasonographically-guided internal jugular vein catheterization in the emergency department increases success rates and reduces complications: a randomized, prospective study. *Ann Emerg Med* 2006;48:540-7.
- [11] Howes B, Dell R. Ultrasound to detect incorrect guidewire positioning during subclavian line insertion. *Anaesthesia* 2006;61:615.
- [12] Abboud PA, Kendall JL. Ultrasound guidance for vascular access. *Emerg Med Clin NA* 2004;22:749-73.
- [13] Shiver S, Blaivas M, Lyon M. A prospective comparison of ultrasound-guided and blindly placed radial arterial catheters. *Acad Emerg Med* 2006;13:1275-9.
- [14] Blaivas M, Lyon M. The effect of ultrasound guidance on the perceived difficulty of emergency nurse-obtained peripheral IV access. *J Emerg Nurs* 2006;31:407-10.
- [15] Lyon M, Blaivas M. Intraoral ultrasound in the diagnosis and treatment of suspected peritonsillar abscess in the emergency department. *Acad Emerg Med* 2005;12:85-8.
- [16] Freeman K, Dewitz A, Baker WE. Ultrasound-guided hip arthrocentesis in the ED. *Am J Emerg Med* 2007;25:80-6.
- [17] Roy S, Dewitz A, Paul I. Ultrasound-assisted ankle arthrocentesis. *Am J Emerg Med* 1999;17:300-1.
- [18] Ferre RM, Sweeney TW. Emergency physicians can easily obtain ultrasound images of anatomical landmarks relevant to lumbar puncture. *Am J Emerg Med* 2007;25:291-6.
- [19] Blaivas M, Sama AE. Ultrasonography in the detection of the cricoid membrane for needle cricothyrotomy. *Acad Emerg Med* 2001;8:579-80.
- [20] Levin WJ, Levitan RM, Kinkle WC, et al. Handheld ultrasonography for the localization of the cricothyroid membrane. *Acad Emerg Med* 2004;11:522.